

Rehabilitation Guidelines for ACL Reconstruction in the Adult Athlete (Skeletally Mature)

Anterior cruciate ligament (ACL) injuries affect men and women across a wide age range and at all levels of athletics.

About the Anterior Cruciate Ligament (ACL)

There are four main ligaments that stabilize the knee. The ACL is located in the center of the knee along with the posterior cruciate ligament (PCL). The ACL is responsible for stabilizing knee rotation that occurs during cutting and pivoting activities. The ACL is also a secondary restraint to knee hyperextension.

The ACL stabilizes the knee joint in two ways. First, the ligament acts as a passive restraint to excessive movement through its connection to the shin bone (tibia) and thigh bone (femur). Second, the ACL has mechanically sensitive nerve receptors, called proprioceptors, which sense the position of a joint. When a joint starts to exceed its normal range or speed of movement these proprioceptors will send a signal to the brain and spinal cord, which in turn stimulates the appropriate musculature to assist with stabilizing the joint.

Mechanism of Injury

An ACL injury usually occurs without contact from another player. The most common form of non-contact injury is a deceleration injury. An athlete often plants

their foot on the ground to cut or change directions and the ACL cannot withstand the force placed on it, so it tears. This causes the knee to buckle or give out. The ACL also can be torn if the knee is forcefully hyperextended while landing from a jump. An ACL injury causes pain and a lot of swelling in the knee. Sometimes people say they felt or heard a “pop” in the knee. It is often hard to walk after an ACL tear. It is also usually hard to bend and straighten the knee all the way after the injury. Even once swelling goes down, people may feel like the knee “gives out” or feels unstable.

Although less common, contact ACL injuries occur. A common contact injury occurs when an athlete is hit from the side at the knee with the foot planted on the ground. These injuries often involve more than one ligament.

Research studies have attempted to determine what factors contribute to an increased injury risk, but ACL injuries are multi-factorial and cannot be isolated to a single cause.

Diagnosis of an ACL Injury

There are several ways to diagnose an ACL injury. A thorough history of how the injury occurred is important to know, but the physical examination is often the most reliable and least expensive method of diagnosis. A sports medicine physician, physical therapist or

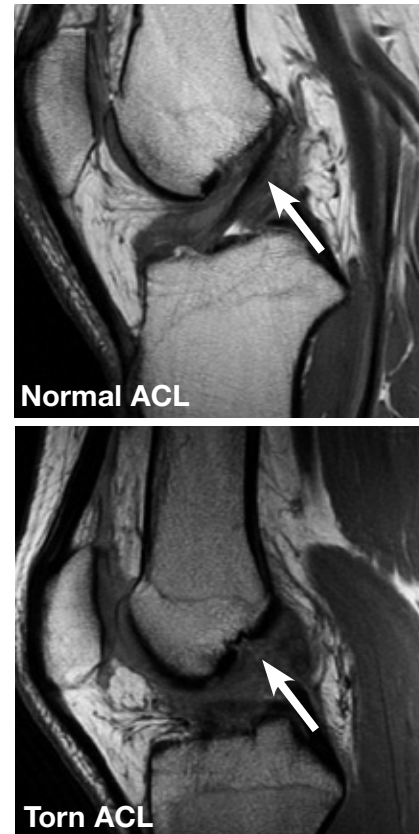

Figure 1: MRI images of the ACL of the knee

athletic trainer will assess the knee’s laxity, compared to the uninjured knee, using a Lachman’s test and an anterior drawer test. They will also test the rotational stability component with a test called the pivot shift test. This test attempts to reproduce the athlete’s sensation of buckling or giving out.

A magnetic resonance imaging (MRI) scan (see Figure 1) can visualize soft tissue and is a relatively accurate test in predicting an ACL tear. A KT-1000 is a device

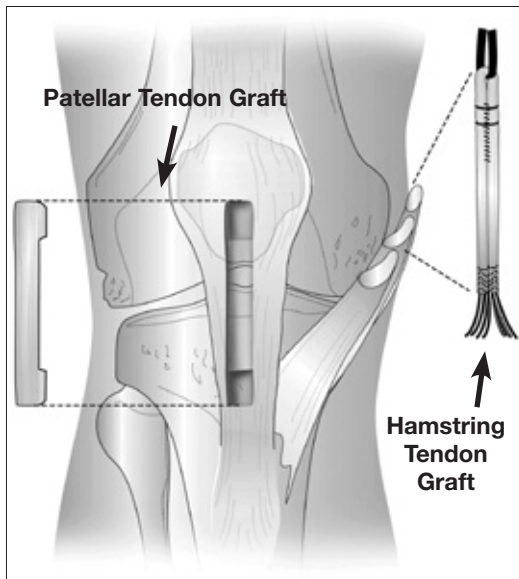


Figure 2: Donor sites for patellar tendon and hamstring tendon grafts

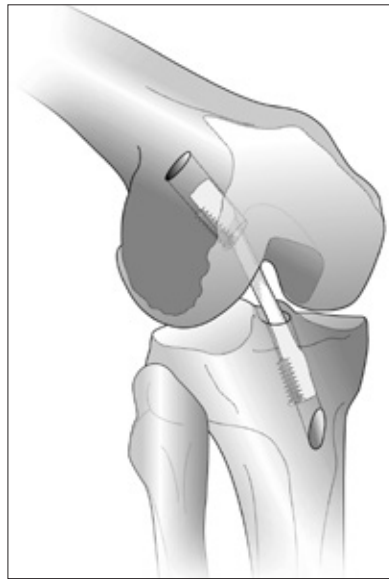


Figure 3: Example of a bone-patellar tendon-bone graft using two interference screws

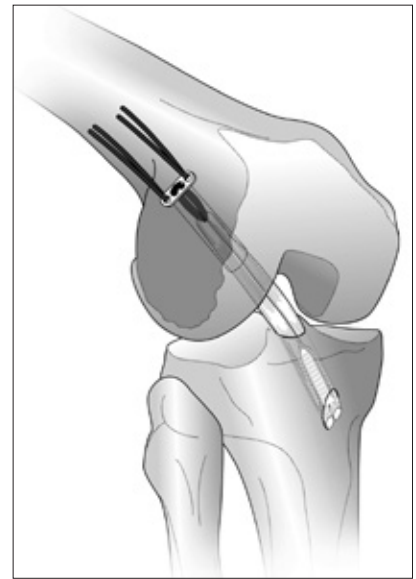


Figure 4: Example of a hamstring tendon graft using an endobutton on the femoral side and a interfix screw on the tibial side screws

that measures the laxity or looseness in the uninjured knee compared to the injured knee. In a diagnostic arthroscopy, a surgeon looks inside the knee with a camera to determine an injury. This is the most definitive test but also the most expensive and invasive.

Consequences of an ACL Injury

When treating an ACL injury, the key is controlling the instability of the knee. Repeated instability not only hinders athletic performance, but more importantly increases the risk of further injury to the cartilage and other ligaments of the knee. Cutting and pivoting activities (common in sports like football, soccer, basketball and volleyball) are the most stressful for the ACL and are the activities most likely to reproduce the instability in an athlete with a torn ACL.

Treatment Options for an ACL Injury

The choices for treatment should be individualized and should take

into account the age, activity level and the desire to return to sports which require significant amounts of cutting and pivoting or other high-speed movements. One form of conservative treatment is to modify the athlete's sports participation. This involves discontinuing sports involving cutting and pivoting, such as soccer and basketball. These sports could be replaced by sports that do not involve cutting and pivoting, such as swimming or running. Another form of conservative treatment is rehabilitation. Rehabilitation for an ACL injury focuses on improving an athlete's proprioception and reactive muscular stabilization. For sports such as basketball, soccer and football, rehabilitation alone may not be enough to prevent instability. If instability persists, the athlete must undergo surgical reconstruction of the ligament to return to these sports.

Surgical reconstruction involves replacing the torn ACL with a graft.

For the athlete that is done, or nearly done growing, the surgical reconstruction involves placing a graft within drill holes (tunnels) in the thigh (femur) bone and shin (tibia) bone. There are several acceptable graft choices: hamstring tendon, patellar tendon and quadriceps tendons. Factors such as; other current injuries to the knee (ie. meniscus or MCL), pre-existing injuries, work or sport returning to, and age may determine which of these three is best for you (See Figures 2-4).

All athletes will undergo six to twelve months of physical therapy. The post-operative physical therapy can be divided into five phases. During the first phase, the rehabilitative goals include protecting the healing graft, improving range of motion, decreasing swelling and regaining leg muscle control. It is especially important to regain full extension very early post-operatively. When the knee is fully extended (straight) the ACL sits against the

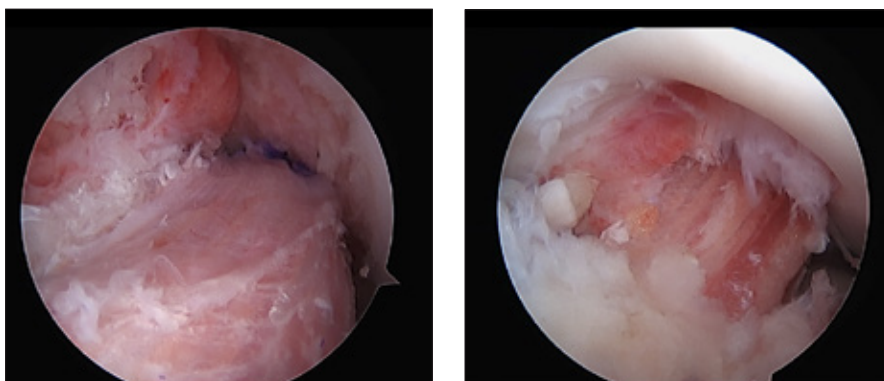


Figure 5: Photos show the ACL graft, with the first photo shot with the knee in flexion and the second photo shot with the knee in full extension.

roof of the intracondylar notch. Thus it is important to achieve this early on, preventing scar tissue from forming in that space of the notch. (See Figure 5, ACL in flexion and in full extension). In phase two, the goal is to focus on restoring proper body alignment and control with basic movements, such as walking, squats and balance. This phase continues to build lower extremity and core (trunk) strength. In phase three, the focus shifts to developing good movement control with impact activities and more complex movements, such as a lunge with a rotational component. Developing movement control and eliminating apprehension while cutting and pivoting is the primary goal of phase four. At this time there is also more

focus on single leg impact and push off with change of direction. The final phase transitions the athlete from performing intense cutting and pivoting activities in a controlled environment to an environment that more closely replicates their sport, including return to team practices with progressive decrease in limitations.

With the return to sports and higher-level activities, there is the risk of the new ACL graft tearing if there is a new injury to the knee. The risk of this happening in young athletes/individuals (< 18 years old) is at least twice as high as it is in older adults. It is reported to be as high as 15-30% in these younger individuals. Reasons for this are unclear but likely to do a few different things

including the type of surgery, continued physical maturation and return to more years of high-level activity. Because of this high risk or re-injury, your physical therapist and doctor will put you through a series of progressive tests to determine when it is most safe to return to activity and sports. There is good evidence to show that the risk of re-injury goes down significantly by passing all return to sport testing and not going back too early.

Rehabilitation Guidelines for ACL Reconstruction in the Adult Athlete (Skeletally Mature)

PHASE I (Surgery to 4 weeks after surgery)

Appointments	<ul style="list-style-type: none"> • Rehabilitation appointments begin post-op day 1 and should be 1- 2 times per week during this phase.
Rehabilitation Goals	<ul style="list-style-type: none"> • Protection of healing graft fixation • Restore quadriceps function and leg control • Adherence to home exercise program (HEP) and precautions
Precautions	<ul style="list-style-type: none"> • <u>Weightbearing</u>: Weight bearing as tolerated (WBAT) with crutches • <u>Brace</u>: Post-operative extension brace for 2-4 weeks, wean from brace locked to brace unlocked to no brace as patient establishes leg control, pain control and safe gait mechanics. • <u>Range of Motion (ROM)</u>: Goal of 0-90° within 1 week, moving toward full flexion after the first 4 weeks. The goal in the first phase is to achieve hyperextension equal to the other side, unless excessive hypermobility exists. Generally 5° of hyperextension should be a maximum. • <u>Hamstring grafts</u>: Avoid aggressive hamstring sets, heel slides, prone hangs and other hamstring activities that may aggravate the graft donor site. Slowly and progressively build in hamstring work. • <u>Mensical Repair</u>: <ul style="list-style-type: none"> • For Drs. Baer, Walczak and Spiker- no weightbearing flexion, respect and don't push through any compression type pain or discomfort when working on flexion range of motion • Dr. Scerpella- no change in precautions • <u>Mensical ROOT Repair</u>: <ul style="list-style-type: none"> • Touch-down weight bearing (TDWB) in locked extension brace for 6 weeks. NWB flexion for 6 weeks • ROM 0-90°, always in NWB position
Suggested Therapeutic Exercise	<ul style="list-style-type: none"> • Assisted range of motion (AROM) (seated knee flexion or supine wall slides) within above guidelines • Knee extension range of motion (avoid hyperextension past 5°) • Ankle pumps progressing to resisted ankle range of motion • Patellar mobilizations • Quad sets - 10 second sustained and 1 second rapid activation • Straight leg raises in multiple directions • Supine wall pushes • Mini squats • Weight shifting drills
Cardiovascular Exercise	<ul style="list-style-type: none"> • None at this time

Rehabilitation Guidelines for ACL Reconstruction in the Adult Athlete (Skeletally Mature)

Progression Criteria	<ul style="list-style-type: none"> • 4+ weeks AND: <ol style="list-style-type: none"> 1. Good quad set and open chain leg control 2. Full knee extension 3. Near normal gait without crutches 4. Minimal knee effusion
----------------------	--

PHASE II (begin after meeting Phase I criteria, usually 4 weeks after surgery)

Appointments	<ul style="list-style-type: none"> • Rehabilitation appointments are 1-2 times per week
Rehabilitation Goals	<ul style="list-style-type: none"> • Normalize gait • Avoid overstressing the fixation site • Closed chain leg control for non-impact movement control • Adherence to HEP
Precautions	<ul style="list-style-type: none"> • Full weight bearing • Avoid over-loading the fixation site by utilizing low amplitude low velocity movements. • No active inflammation or reactive swelling.
ROM Exercises	<ul style="list-style-type: none"> • Supine wall slides, heel slides and knee to chest to improve knee flexion as needed. Full extension should be gained by this point. • Stationary bike with low resistance • Aquatic therapy as needed
Suggested Therapeutic Exercise	<ul style="list-style-type: none"> • Gait drills - forward and backward march walk, soldier walk, side step, step overs, hurdle walk • Double leg balance drills - balance board, tandem balance, progressing to stationary single leg balance drills • Weight acceptance and control - shallow squat with lateral shifting, with sagittal shift, with shallow arc motions • Closed chain strengthening for quadriceps and glutes - double leg squat progressions, split squats, step backs, leg press • Begin to use external focus of attention drills for double leg strengthening • Double leg heel raises • Bridging • Hip and core strengthening
Cardiovascular Exercise	<ul style="list-style-type: none"> • Stationary bike with low resistance • Deep water running • Elliptical trainer
Progression Criteria	<ul style="list-style-type: none"> • Normal gait • Symmetric weight acceptance for squats to 60° • No reactive swelling after exercise or activity that lasts for more than 12 hours.

Rehabilitation Guidelines for ACL Reconstruction in the Adult Athlete (Skeletally Mature)

PHASE III (begin after meeting Phase II criteria, usually 11-12 weeks after surgery)

Appointments	<ul style="list-style-type: none"> • Rehabilitation appointments as needed. Usually 1 time every 1-2 weeks.
Rehabilitation Goals	<ul style="list-style-type: none"> • Normal running gait without side to side differences or compensations. • Normal double leg landing control without side to side differences or compensations for sub-maximal squat jump. • Adherence to HEP
Precautions	<ul style="list-style-type: none"> • No active reactive swelling or joint pain that lasts more than 12 hours.
Suggested Therapeutic Exercise	<ul style="list-style-type: none"> • Low amplitude low velocity agility drills: forward and backward skipping, side shuffle, skater's quick stepping, carioca, cross overs, backward jog, forward jog • Closed chain strengthening for quadriceps and glutes - progressing from double leg strengthening to single leg strengthening; lunge progressions and single leg squat progressions • Single leg balance exercises and progressions, progressing from stationary to deceleration in to holding posture and position • At ~12-14 weeks initiate low amplitude landing mechanics: med ball squat catches, shallow jump landings, chop and drop stops, etc. • Hip strengthening - especially oriented at neuromuscular control in prevention of hip adduction at landing and stance • Core strength and stabilization - especially orientated at preventing frontal plane trunk lean during landing and single leg stance
Cardiovascular Exercise	<ul style="list-style-type: none"> • Stationary bike with moderate resistance • Deep water running and swimming • Elliptical trainer at moderate intensity
Progression Criteria	<ul style="list-style-type: none"> • Normal jogging gait • Good single leg balance • Less than 25% deficit on Biodex strength test • No reactive swelling after exercise or activity

Rehabilitation Guidelines for ACL Reconstruction in the Adult Athlete (Skeletally Mature)

PHASE IV (begin after meeting Phase III criteria, usually 16-20 weeks after surgery)

Appointments	<ul style="list-style-type: none"> • Rehabilitation appointments are once every 2-4 weeks
Rehabilitation Goals	<ul style="list-style-type: none"> • Normal multi-planar high vel without side to side differences or compensations. • Normal double leg landing control without side to side differences or compensations. • Adherence to HEP
Precautions	<ul style="list-style-type: none"> • No active reactive swelling or joint pain that lasts more than 12 hours.
Suggested Therapeutic Exercise	<ul style="list-style-type: none"> • Progressive agility drills: forward and backward skipping, side shuffle, skater's quick stepping, carioca, cross overs, backward jog, forward jog • Landing mechanics - progressing from higher amplitude double leg to single leg landing drills. Start uni-planar and gradually progress to multi-planar • Movement control exercise beginning with low velocity, single plane activities and progressing to higher velocity, multi-plane activities • Unanticipated movement control drills, including cutting and pivoting • Agility ladder drills • Strength and control drills related to sport specific movements. • Sport/work specific balance and proprioceptive drills • Hip strengthening - especially oriented at neuromuscular control in prevention of hip adduction at landing and stance • Core strength and stabilization - especially orientated at preventing frontal plane trunk lean during landing and single leg stance • Stretching for patient specific muscle imbalances
Cardiovascular Exercise	<ul style="list-style-type: none"> • Progressive running program. Design to use sport specific energy systems
Progression Criteria	<ul style="list-style-type: none"> • Patient may return to sport after receiving clearance from the orthopedic surgeon and the physical therapist/athletic trainer. Progressive testing will be completed. The patient should have less than 15% difference in Biodex strength test, force plate jump and vertical hop tests, and functional horizontal hop tests.

Rehabilitation Guidelines for ACL Reconstruction in the Adult Athlete (Skeletally Mature)

PHASE V (begin after meeting Phase IV criteria, usually 24-32 weeks after surgery)

This phase is individualized based on the athlete's sport and continued physical impairment/performance needs. During this phase athletes will be allowed to return to team practices with criteria and limitations from the physical therapist. This may include time, volume or specific activity.

Practice Continuum:

1. Movement Patterns: a. sprinting b. shuffle c. carioca d. zig-zag cutting and e. shuttle change of direction
2. Closed Drills – sport-specific drills without opposition in a controlled speed environment
3. One-on-one Drills (no-contact) – sport-specific drills/ activities where the athlete is expected to react to his/ her opponent without compensation
4. One-on-one Drills – full speed 1 on 1 drills with game necessary contact
5. Team Scrimmage (no-contact) – patients are asked to wear a different colored jersey to indicate their contact restrictions during team scrimmaging when appropriate
6. Team Scrimmage – full scrimmaging
7. Restricted Play – progressing time and situational play as appropriate.
8. Full return to play

Patient may return to sport after receiving clearance from the orthopedic surgeon and the physical therapist/athletic trainer. Progressive testing will be completed. Patient should have less than 15% difference in Biodex strength test, force plate jump and hop tests and functional hop tests.

These rehabilitation guidelines were developed collaboratively by UW Health Sports Rehabilitation and the UW Health Sports Medicine physician group.

Updated 1/2018

REFERENCES

1. Busam ML, Provencher MT, Bach BR, Jr. Complications of anterior cruciate ligament reconstruction with bone-patellar tendon-bone constructs: care and prevention. *Am J Sports Med.* Feb 2008;36(2):379-394
2. Cooper RL, Taylor NF, Feller JA. A systematic review of the effect of proprioceptive and balance exercises on people with an injured or reconstructed anterior cruciate ligament. *Res Sports Med.* Apr-Jun 2005;13(2):163-178
3. Krych AJ, Jackson JD, Hoskin TL, Dahm DL. A meta-analysis of patellar tendon autograft versus patellar tendon allograft in anterior cruciate ligament reconstruction. *Arthroscopy.* Mar 2008;24(3):292-298
4. Moiala AS, Jarvela T, Kannus P, Jarvinen M. Muscle strength evaluations after ACL reconstruction. *Int J Sports Med.* Oct 2007;28(10):868-872
5. Myer GD, Paterno MV, Ford KR, Hewett TE. Neuromuscular training techniques to target deficits before return to sport after anterior cruciate ligament reconstruction. *J Strength Cond Res.* May 2008;22(3):987-1014
6. Myer GD, Paterno MV, Ford KR, Quatman CE, Hewett TE. Rehabilitation after anterior cruciate ligament reconstruction: criteria-based progression through the return-to-sport phase. *J Orthop Sports Phys Ther.* Jun 2006;36(6):385-402
7. Palmieri-Smith RM, Thomas AC, Wojtyls EM. Maximizing quadriceps strength after ACL reconstruction. *Clin Sports Med.* Jul 2008;27(3):405-424, vii-ix
8. Pinczewski LA, Lyman J, Salmon LJ, Russell VJ, Roe J, Linklater J. A 10-year comparison of anterior cruciate ligament reconstructions with hamstring tendon and patellar tendon autograft: a controlled, prospective trial. *Am J Sports Med.* Apr 2007;35(4):564-574
9. Mininder S, Kocher, Sumeet Garg and Lyle J. Micheli, Physeal Sparing Reconstruction of the Anterior Cruciate Ligament In Skeletally Immature Prepubescent Children and Adolescents. Surgical Technique. *J Bone Joint Surg Am.* 2006;88:283-293. doi: 10.2106/JVJA.D.0044

At UW Health, patients may have advanced diagnostic and/or treatment options, or may receive educational materials that vary from this information. Please be aware that this information is not intended to replace the care or advice given by your physician or health care provider. It is neither intended nor implied to be a substitute for professional advice. Call your health provider immediately if you think you may have a medical emergency. Always seek the advice of your physician or other qualified health provider prior to starting any new treatment or with any question you may have regarding a medical condition.

Copyright 2018 UW Health Sports Medicine